A RADIOLOGIC METHOD FOR EXAMINATION OF THE GASTROINTESTINAL TRACT IN THE ATLANTIC RIDLEY, *LEPIDOCHELYS KEMPI*, AND LOGGERHEAD, *CARETTA CARETTA*, MARINE TURTLES[1,2]

In the past 2 yr the National Marine Fisheries Service of the U.S. Department of Commerce has been raising hatchlings of the Atlantic ridley, *Lepidochelys kempi*, and loggerhead, *Caretta caretta*, marine turtles. These are classified as endangered and threatened species under the U.S. Endangered Species Act of 1973 (U.S. Fish and Wildlife Service 1977, 1978). The rearing activity was undertaken to provide a better understanding of the early life histories of those species.

Of immediate concern was the evaluation and treatment of skin, gastrointestinal, lung, and systemic diseases, which emerged rapidly in the captive turtles. Radiologic examination was sought as a possible diagnostic modality for various problems. To this end we have attempted to develop radiologic techniques for the study of normal and diseased animals.

In this paper we report on the use of barium sulfate contrast agent in studying the gastrointestinal (GI) tract of normal turtles and propose its use as an aid in the diagnosis of turtle GI diseases.

Methods

The GI tracts of two loggerhead and two ridley turtles, between the ages of 4 and 10 mo, were examined by means of commercially available 44% (wt/wt) aqueous barium sulfate suspension.[3] Similar suspensions are frequently used in the examination of the GI tract of humans (Margulis 1973; Miller 1973).

Preparation of the GI tract was accomplished by not feeding the animals for 2 d and then giving 0.5 ml of X-Prep, a commercial laxative of extract of senna fruit (Gray Pharmaceutical Company, Norwalk, Conn.), on the day prior to the examination. Next, the esophagus was intubated using a plastic umbilical artery catheter (Argyle, Cat. No. 8888-160-226, Sherwood Medical Co., St. Louis, Mo.) measuring 5 mm in circumference. The intubation of the ridley turtle's esophagus proved more difficult than the loggerhead's as they resisted passage of the catheter through the oropharynx. Therefore, a dose of 0.25 mg of succinylcholine chloride[4] was given subcutaneously in the neck to effect partial skeletal muscle paralysis. Paralysis was adequate in 4 or 5 min, rapidly diminished, and was nearly undetectable in 20 min. (No untoward side effects occurred.) Also, a plastic hollow guide (4 mm in diameter) was placed in the oropharynx and upper esophagus through which the umbilical artery catheter was threaded into the esophagus and stomach. Both the hollow guide and catheter were lubricated with small amounts of surgical lubricant. The placement of the catheter tip in the stomach and injection of approximately 5 ml of contrast material were done under fluoroscopic control. Radiographic films were then exposed using either the phototimed fluoroscopic filming device or manual techniques utilizing standard radiographic equipment, film, and film cassettes. The fluoroscopic unit, radiographic equipment, radiographic film, and film cassettes which were used are of standard medical grade and are available in most radiology departments. Serial filming consisting of fluoroscopic spot films, made in various degrees of obliquity and standard medical radiographic film[5] in cassettes (Halsey Rigidform, Halsey X-Ray Products, Brooklyn, N.Y.) equipped with par speed intensifying screens (Radelin TA-3, GAF Corp., Brooklyn, N.Y.), and industrial grade film[6] in cardboard cassettes made in the dorsoventral (DV) position were done on the day of the examination. For the following 2 d DV par speed medical films or industrial grade films were made on each consecutive day. Thereafter, DV films were exposed every other day for 4 d. Radiographic technique and film types are given in Table 1.

Radiation exposure using industrial film exposed at 60 kV peak and 400 mAs and par speed medical film exposed at 50 kV peak and 10 mAs with a target film distance of approximately 100 cm was 0.98 and 0.14 Roentgen/exposure, respectively. These measurements were obtained using a 0.6 cm^3 Baldwin-Farmer air ionization chamber

[1]The investigations involving the Atlantic ridley turtle were conducted under Permit No. PRT 2-1770 (U.S. Federal Fish and Wildlife Service), permits 1978-ABC-IV-0751, No. 27611-8786, and 1979-ABC-IV-1258, Exp. 4287 (Mexican Government).

[2]Contribution Number 81-1G, Southeast Fisheries Center Galveston Laboratory, National Marine Fisheries Service, NOAA.

[3]E-Z-EM Company, Cat. No. 750, Westbury, N.Y. Reference to trade names or commercial companies does not imply endorsement by the National Marine Fisheries, NOAA.

[4]Succinylcholine HCl injection U.S.P., Oraganon, Inc., West Orange, N.J.

[5]Kodak XRP-1, Eastman Kodak Co., Rochester, N.Y.

[6]Kodak RP/M, Eastman Kodak Co., Rochester, N.Y.

TABLE 1.—Radiographic technique for turtle examinations.

Weight (g)	Carapace length (cm)	Turtle position	Voltage (kV)	Current (mAs)	Tube-film distance (cm)	Film type
400	15.0	DV[1]	60	400	100	Industrial
300	12.5	DV	50-55	300-360	100	Industrial
350	13.5	DV	50	40	100	Industrial
400	13.0	DV	50	10	100	Medical
300-400	13-15	Variable	55-60	Phototimed (fluoroscopy unit)	—	Medical

[1]DV = Dorsoventral projection.

(Nuclear Enterprises, Inc., San Carlos, Calif.) on an electrometer[7] at 300 V collection potential.

Results

Adequate clearing of food residue was obtained after the subjects were prepared in the manner described in Methods. The experimental animals were quite small (0.3-0.4 kg) and good resolution and detail are a necessity if mucosal detail is to be adequately examined and appraised. Excellent detail of the esophagus, stomach, and small intestinal mucosa was obtained by using industrial grade film while adequate detail was obtained on par speed medical film. The radiologic anatomy of the esophagus, stomach, and small intestine correlated well with the findings noted at gross necropsy of turtles of similar age and size that had

[7]Model 602 Electrometer, Keithley Co., Cleveland, Ohio.

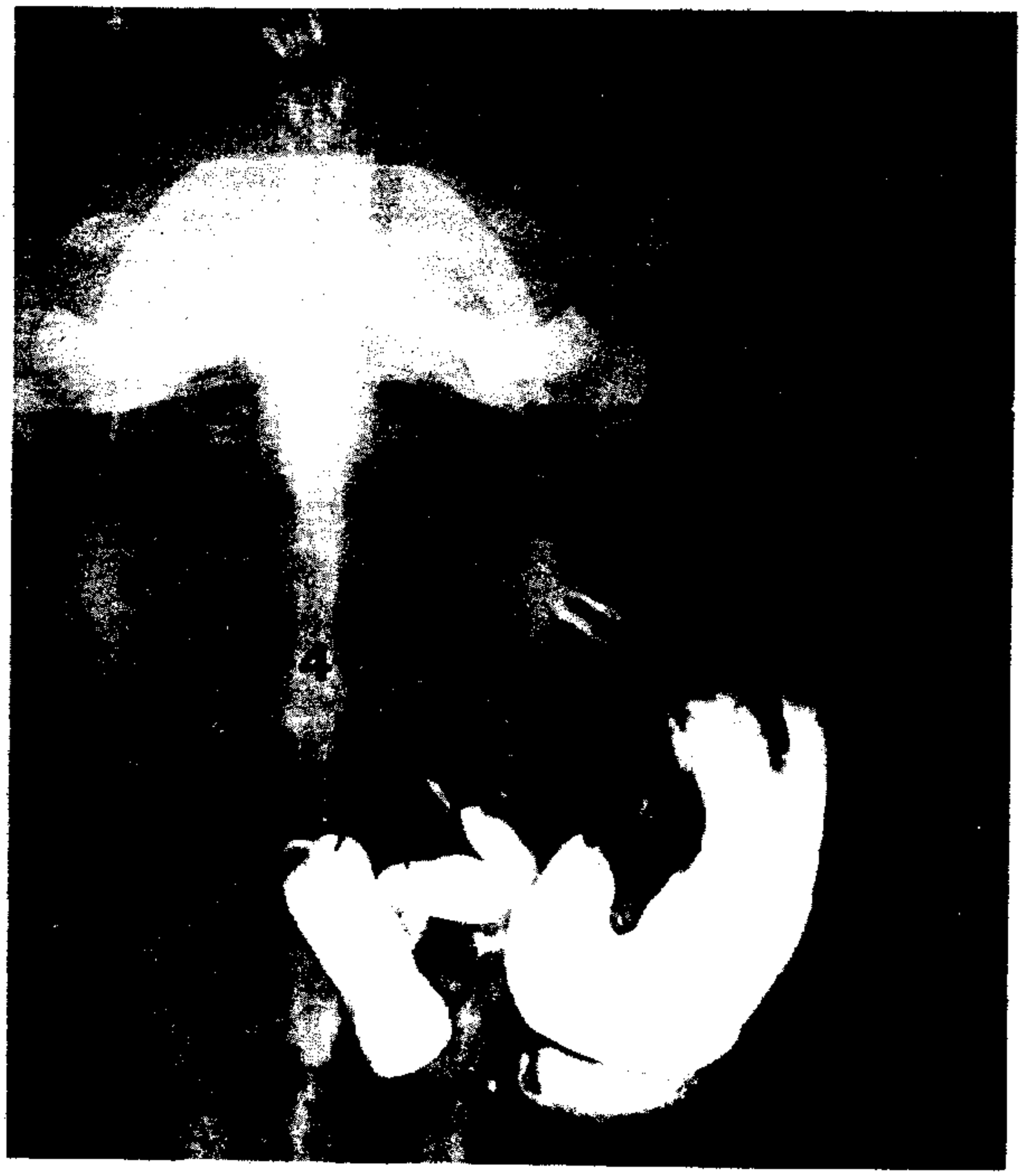

FIGURE 1.—Dorsoventral view of a 15 cm carapace length, 400 g, 8-mo-old loggerhead turtle made on the second day after barium instillation. Industrial grade film was used for this exposure. 1—stomach, 2—proximal small bowel, 3—tracheal air shadow, 4—lungs. The arrowheads demonstrate the longitudinal mucosal pattern in the proximal small bowel (1.8 ×).

died of various causes. Figure 1 shows the relatively smooth mucosa of the stomach which has been distended with barium. The smooth longitudinal folds of the proximal small bowel are also easily identified. Also in Figure 1 just to the left of the tracheal air shadow (3) and superimposed over the cervical vertebrae, a few esophageal papillae are faintly outlined by small amounts of barium. Incidently, injection of contrast directly into the esophagus demonstrated the esophageal papillae and the narrowing in the region of the gastroesophageal junction with greater clarity than in Figure 1. The size and position of the GI structures were also easily assessed. Continued filming over several days demonstrated slow progression of the barium sulfate suspension through the small intestine into the colon. In the colon residual fecal contents mixed with the barium and obscured the mucosal detail somewhat. Transit time was noted to be at least 4 or 5 d from the stomach to the proximal colon in all four animals studied.

Discussion

The radiologic examination of the upper GI tract of marine turtles by using barium sulfate as a contrast material provides a potential tool in the evaluation of various diseases in turtle populations. The radiographic information from these studies should aid in evaluating turtles for partial or complete small bowel obstruction, with associated changes in motility and bowel size, and foreign bodies within the intestinal tract such as parasites or bezoars. Diseases altering the mucosal pattern such as ulceration, gastritis, enteritis, or colitis caused by various infectious or inflammatory processes could be demonstrated. The disease states listed above are frequently demonstrated by similar GI studies performed in humans (Paul and Juhl 1972).

The use of succinylcholine chloride in these animals should be approached with caution. The total dose should be divided and given incrementally over 3-5 min until the desired effect is obtained. The use of a well lubricated plastic hollow guide is recommended prior to the decision to use a paralytic agent.

Radiation exposure was of concern but the calculated doses of 0.98 and 0.14 Roentgen/exposure for industrial and par speed medical film were well below the harmful radiation dose in several species of turtles found by Altland et al. (1951) and Cosgrove (1971). They resemble dosage levels used by Gibbons and Greene (1979), which produced no apparent harm to the freshwater turtles in their study. To reduce radiation exposure during the examination the use of par speed medical film which requires a lower radiation dose is recommended when the clinical situation permits. For instance, intestinal obstruction would require only par speed medical film technique, as demonstration of mucosal detail would be unnecessary when assessment of dilatation of the bowel, stasis of contents, and site of the obstructing process would be primary concerns. In examinations where mucosal detail is desirable such as detection of small ulcerations, industrial film and its attendant higher exposures may become necessary.

Acknowledgments

We appreciate the help, encouragement, and support of M. H. Schreiber, Chairman, Department of Radiology, University of Texas Medical Branch, (UTMB), as well as his comments on preparation of this paper; to Robert Perry, health physicist, Department of Radiology, UTMB, for his assistance in taking and calculating the radiation doses; and to Peggy Seibel, residents' secretary, UTMB, for typing the manuscript.

Literature Cited

ALTLAND, P. D., B. HIGHMAN, AND B. WOOD.
1951. Some effects of x-irradiation on turtles. J. Exp. Zool. 118:1-19.

COSGROVE, G. E.
1971. Reptilian radiobiology. J. Am. Vet. Med. Assoc. 159:1678-1684.

GIBBONS, J. W., AND J. L. GREENE.
1979. X-ray photography: a technique to determine reproductive patterns of freshwater turtles. Herpetologica 35:86-89.

MARGULIS, A. R.
1973. Use of iodinated water-soluble contrast agents in acute gastrointestinal disease. *In* A. R. Margulis and H. J. Burhenne (editors), Alimentary tract roentgenology. Vol. 1, p. 271-280. 2d ed. C. V. Mosby Co., St. Louis, Mo.

MILLER, R. E.
1973. Barium sulfate as a contrast medium. *In* A. R. Margulis and H. J. Burhenne (editors), Alimentary tract roentgenology. Vol. 1, p. 114-126. 2d ed. C. V. Mosby Co., St. Louis, Mo.

PAUL, L. W., AND J. H. JUHL.
1972. The abdomen and gastrointestinal tract. *In* The essentials of roentgen interpretation, p. 411-643. 3d ed. Harper and Row, Hagerstown, Md.

U.S. FISH AND WILDLIFE SERVICE.
1977. A guide to endangered species regulations—The

Endangered Species Act (with attachment: 50 CFR17 (Rev. 8/77), p. 1-16.
1978. The Endangered Species Act—The green loggerhead, and olive (Pacific) ridley sea turtles. T-1, p. 1-3.

G. L. MCLELLAN

Department of Radiology
University of Texas Medical Branch
Galveston, TX 77550

J. K. LEONG

Southeast Fisheries Center Galveston Laboratory
National Marine Fisheries Service, NOAA
Galveston, TX 77550